

The effect of lateral opening wedge distal femoral osteotomy on medial knee opening: clinical and biomechanical factors

Iftach Hetsroni · Stephen Lyman · Andrew D. Pearle · Robert G. Marx

Received: 31 August 2012 / Accepted: 14 January 2013
© Springer-Verlag Berlin Heidelberg 2013

Abstract

Purpose The case of a patient with knee valgus and instability due to combined ACL–MCL laxity who underwent lateral opening wedge distal femoral osteotomy (DFO) is presented. The symptoms of instability resolved following the surgery. It was unclear whether the increase in valgus stability was related only to a decrease in valgus moments during stance or also to a medial tensioning effect. We therefore performed a laboratory cadaveric study. The purpose of this study was to examine whether after MCL and ACL sectioning, lateral opening wedge DFO would result in decrease in medial opening under static conditions of valgus stress.

Methods Medial knee opening under valgus load of 9.8 Nm was tested in 8 cadaveric specimens in scenarios of MCL and ACL sectioning and compared before and after performing lateral opening wedge DFO.

Results When the superficial MCL was sectioned, medial knee opening in 30° flexion decreased after lateral opening wedge DFO compared to medial opening before the osteotomy (i.e. from $6.5 \pm 0.5^\circ$ to $5.6 \pm 0.5^\circ$, $p = 0.01$). When the superficial MCL, deep MCL, and ACL were all sectioned, medial knee opening in extension decreased

after lateral opening wedge DFO compared to medial opening before the osteotomy but this was not significant (i.e. from $6.8 \pm 0.5^\circ$ to $6.1 \pm 0.5^\circ$, $p = \text{n.s.}$).

Conclusion In superficial MCL-transected knees, medial laxity at 30° of knee flexion decreased after lateral opening wedge DFO. However, the clinical relevance of the laxity decrease observed remains uncertain since the reduction was small in magnitude.

Level of evidence Controlled laboratory study.

Keywords Valgus thrust gait · Distal femoral osteotomy · Medial knee opening · Medial collateral ligament

Introduction

Malalignment should be corrected before ligament reconstruction in cases involving varus knees with anterior cruciate ligament (ACL) and posterolateral ligament deficiencies [1, 3, 16]. These studies demonstrated that correction of alignment with valgus-producing osteotomy can restore stability and avoid the need for subsequent ligament reconstruction in some cases. Recently, a cadaveric study supported this rationale by showing that proximal tibial medial opening wedge osteotomy decreased varus laxity in knees with posterolateral corner ligament deficiency [7].

Compared to lateral ligament laxity in a varus knee, chronic medial laxity (with or without ACL laxity) in a valgus knee is an uncommon condition. According to the limited literature available, varus-producing osteotomy is advised as a first surgical step to improve stability in this rare situation [10, 17]. To produce a varus effect, the osteotomy can be performed at the distal femur using lateral opening [12, 14] or medial closing [9, 14] wedge techniques. While good-to-excellent outcomes were

I. Hetsroni (✉)
Department of Orthopedic Surgery, Meir General Hospital,
Sapir Medical Center, Tsharnichovski Street 59,
44281 Kfar Saba, Israel
e-mail: iftachhetsroni@gmail.com

I. Hetsroni
Sackler Faculty of Medicine, Tel Aviv University,
Tel Aviv, Israel

S. Lyman · A. D. Pearle · R. G. Marx
Hospital for Special Surgery, Weill Medical College of Cornell
University, New York, NY, USA

previously reported with these procedures, these studies addressed valgus knees with lateral compartment arthritis [9, 14] or cases of MCL laxity in patients with congenital or developmental dysplasia [10]. In the case of valgus knee with medial laxity which is not related to lateral arthritis but rather to sports trauma, less data are available, but it is believed that the osteotomy relies on a reduction in tension on the medial collateral ligament as a result of decreased valgus moment during the stance phase of gait [12]. It is unknown, however, whether the improvement in medial stability should be expected under static conditions as well.

Case report

Recently, one of us (***RGM***) treated a 46-year-old female patient that presented 5 months following ACL reconstruction complaining of knee instability. She had valgus alignment, noticed both clinically (Fig. 1a) and on the hip-to-ankle AP radiography (Fig. 1b), a valgus thrust gait, and a failed ACL graft with medial laxity. She was noted to have a relatively hypoplastic lateral femoral condyle on the injured side compared to her other knee as the source for her increased valgus alignment. The patient's complaints of knee instability resolved following a lateral opening wedge distal femoral osteotomy (DFO) which was aimed to lengthen the lateral distal femoral column and result in symmetrical limb alignment (Fig. 1c). Interestingly, we noted a postoperative reduction in medial compartment opening to valgus stress on physical examination once symmetrical limb alignment was achieved. As the patient was doing well, stress radiographs were not indicated at that time. However, the reason for this effect was not clear since the osteotomy was proximal to the femoral insertion of the MCL. This case stimulated us to investigate this phenomenon further with a cadaveric study.

We evaluated whether improved medial stability post-osteotomy could be attributable to a medial tensioning effect in addition to a decreased valgus moment during the stance phase of gait. In this cadaveric study, it was hypothesized that a varus-producing DFO would result in decrease in medial compartment opening under valgus load in scenarios of MCL and ACL transections.

Materials and methods

Specimen set-up

Eight fresh-frozen hip-to-ankle cadaveric specimens with a median age of 58.5 years (range 52–60 years) were used in

this study. Seven were male and one was a female specimen. There were four right and four left side specimens. Each specimen was mounted and secured using a vise attached to the proximal femur, allowing knee flexion from 0 to 110°. A medial parapatellar arthrotomy was performed to confirm that the ligaments were stable and no arthritis was present in the knee by direct inspection. Steinmann pins were placed in the femur and tibia diaphyses to mount reflective markers. Intra-articular geometry was then acquired with a navigation pointer, and a three-dimensional model of the knee was created.

Measurement protocol

To simulate our clinical case which had laxity of the superficial and deep parts of the MCL as well as the ACL, measurements in this cadaveric model were taken in the following seven consecutive scenarios in each specimen to test the effect of sequential sectioning of the superficial part of the MCL, the deep part of the MCL, and the ACL on valgus knee opening with and without a lateral opening wedge DFO:

1. Intact knee, providing reference values (i.e. "Intact" scenario).
2. Superficial MCL (sMCL) was dissected free of the femur (i.e. "Cut sMCL" scenario) (Fig. 2a).
3. Osteotomy was opened laterally to 10° and fixed with a locking lateral distal femur plate (Tomofix lateral distal femur plate, Synthes, 1302 Wrights Lane East West Chester, PA 19380, USA) (i.e. "Cut sMCL + DFO" scenario).
4. Deep MCL (dMCL) was dissected of the femur (i.e. "Cut sMCL + cut dMCL + DFO" scenario) (Fig. 2b).
5. The osteotomy wedge was closed, recreating the normal knee axis, and fixed with a locking distal femur plate to simulate the "intact bone" situation before the osteotomy is opened (i.e. "Cut sMCL + cut dMCL" scenario).
6. ACL was dissected of the femur (i.e. "Cut sMCL + cut dMCL + cut ACL" scenario).
7. The osteotomy was re-opened laterally 10° and fixed with a locking distal femur plate (i.e. "Cut sMCL + cut dMCL + cut ACL + DFO" scenario).

In each scenario, valgus opening [°] was measured under valgus load of 9.8 Nm in accordance with previous protocols [2, 8, 13, 15] that was applied manually to the tibia with a tensiometer parallel to the joint line and at 25 cm distal from the joint (Fig. 3). This was repeated four times in full extension and four times in 30° knee flexion for each specimen.

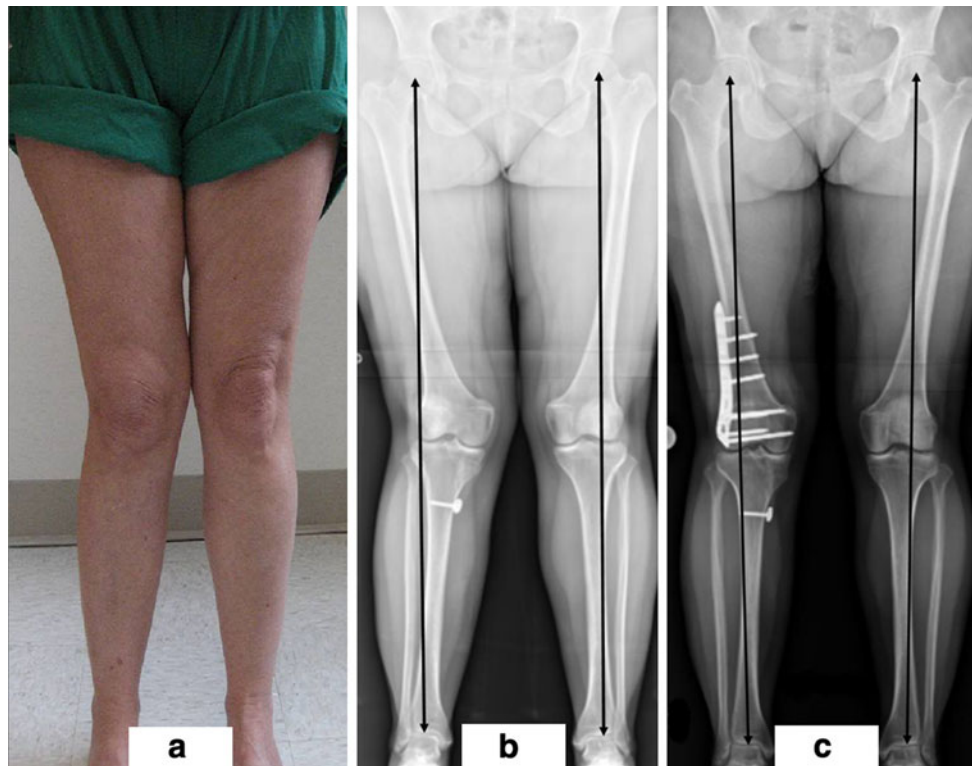


Fig. 1 **a** Patient photograph showing increased valgus alignment of the *right* knee compared to the *left* knee. **b** Preoperative AP hip-to-ankle radiograph showing increased valgus alignment of the *right*

knee compared to the *left* knee. **c** Postoperative AP hip-to-ankle radiograph showing symmetric alignment of the *right* knee compared to the *left* knee

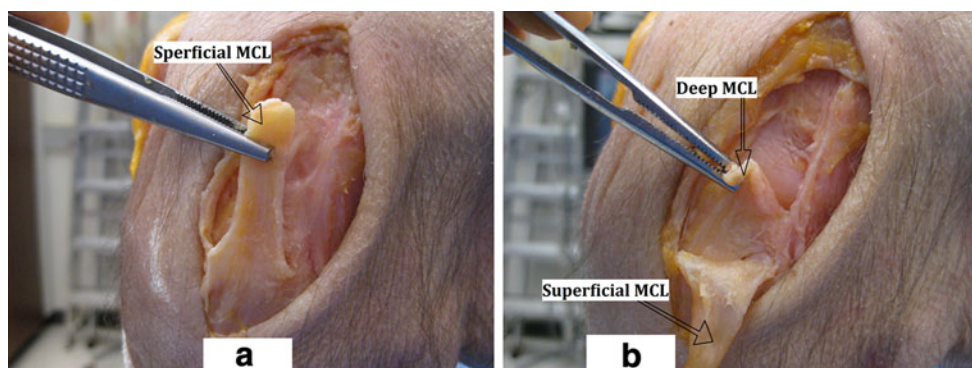


Fig. 2 **a** Superficial MCL is dissected of the femur. **b** Superficial and deep MCL are both dissected of the femur

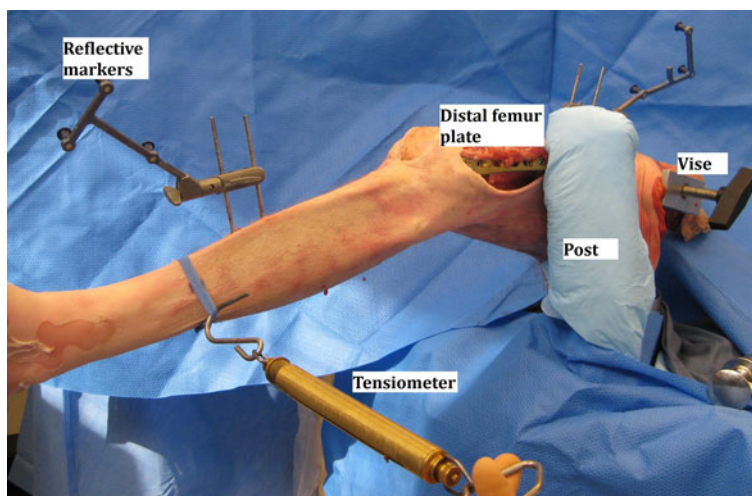
Navigation systems

Two navigation systems were used in this model. The Praxim Total Knee Surgetics Universal navigation application running on the Nanostation surgical navigation system (Praxim, Grenoble, France) was used to measure limb alignment (hip-to-ankle axis) of each specimen and to confirm 10° varus-directed opening of the DFO, as well as the recreation of pre-DFO knee alignment when the osteotomy was closed, simulating the intact bone. A second navigation system, that is, the Praxim Surgetics surgical

navigation system (Praxim, Grenoble, France), was used to acquire the kinematic data (degree valgus opening). This Surgetics ACL Logics Universal Software was used for data acquisition as previously described [2, 11]. This system has been shown to be very precise, within 1° or 1 mm compared with an industrial robotic sensor [5, 6, 11].

Statistical analysis

Valgus opening [°] in 0° and in 30° was measured and compared between the different situations as follows.

Fig. 3 Cadaveric model set-up

Three comparisons were made to assess the effect of sequential ligament sectioning (i.e. cutting the sMCL, then adding dMCL cut, and finally adding ACL cut) on static medial knee stability (without adding a DFO) that included (1) “Intact” knee scenario vs. “Cut sMCL” scenario; (2) “Cut sMCL” scenario vs. “Cut sMCL + cut dMCL” scenario; and (3) “Cut sMCL + cut dMCL” scenario vs. “Cut sMCL + cut dMCL + cut ACL” scenario. Another three comparisons were made to assess the effect of lateral opening wedge DFO on static medial stability in each of the ligament sectioning scenarios that included (1) “Cut sMCL” scenario vs. “Cut sMCL + DFO” scenario; (2) “Cut sMCL + cut dMCL” scenario vs. “Cut sMCL + cut dMCL + DFO” scenario; and (3) “Cut sMCL + cut dMCL + cut ACL” scenario vs. “Cut sMCL + cut dMCL + cut ACL + DFO” scenario. In addition, valgus opening [°] in the “Intact” knee scenario was compared to each of the other six scenarios. Prior to beginning the study, sample size was calculated based on existing data [2]. This showed that in extension, valgus opening was 1.9° (95 % CI 1.3–2.6) in intact knees and 6.9° (95 % CI 5.7–8.1) in MCL-transected knees, whereas in 30° flexion, valgus opening was 2.6° (95 % CI 1.8–3.3) in intact knees and 10.2° (95 % CI 9.2–11.2) in MCL-transected knees. Assuming a 50 % clinically meaningful decrease in valgus opening after a DFO in each scenario compared to before a DFO, performing repeated measures analysis of variance, a minimum sample size of 4 cadavers was needed to provide power of 80 % ($\alpha = 0.05$). A decision was then made to double the number of requested specimens, viewing possible technical errors which could be expected in a set-up of such study (poor tissue quality of the MCL, osteoporotic bone which may fail, etc.).

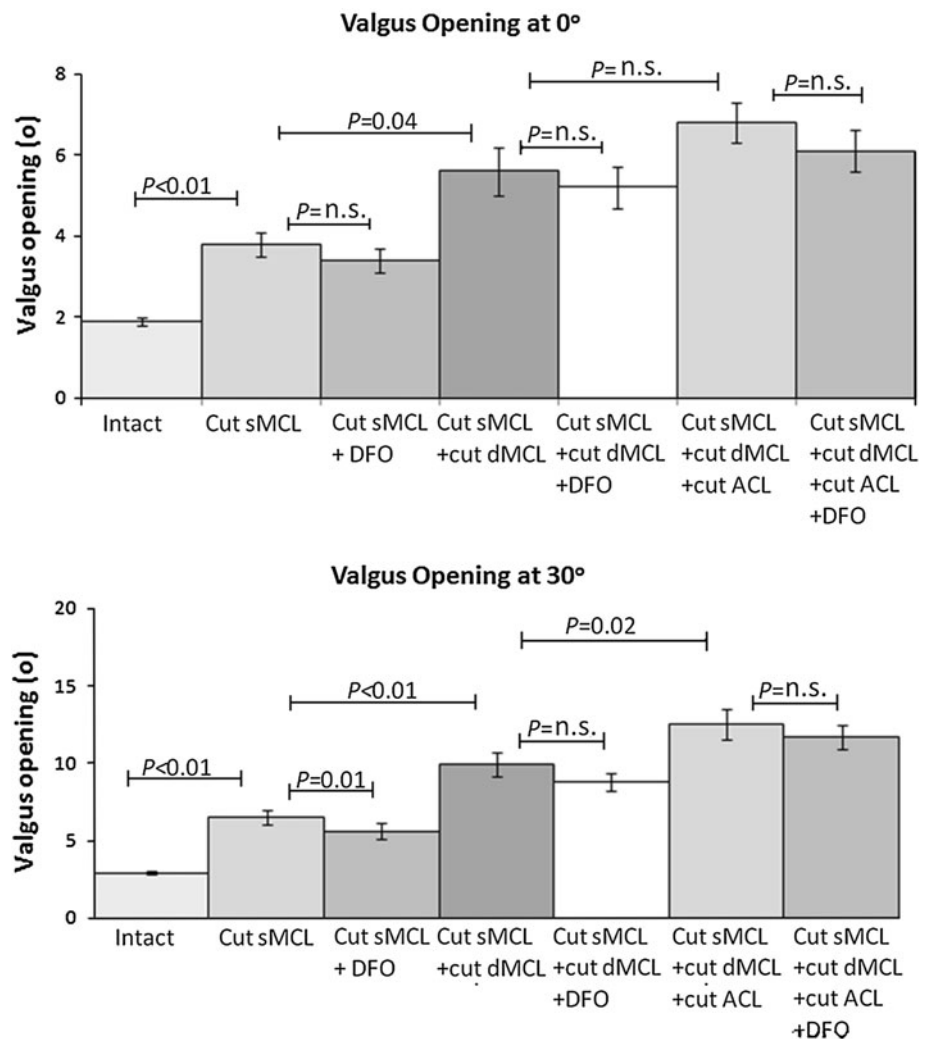
After completing all measurements, statistical analysis was performed using The SAS System for Windows 9.2

(Cary, NC). Due to missing data (data which were not recorded as a result of technical error related to specimen preparation), a repeated measures analysis of variance (rmANOVA) could not be implemented so a generalized estimating equation (GEE) was used to model the effect of each condition on valgus opening. Separate models were calculated for 0 and 30°. GEE is robust for repeated measures data even when missing values are present. Due to the large number of comparisons being made, a false discovery rate (FDR) adjustment was used to reduce the likelihood of a significant finding due to change alone. The FDR-adjusted crucial p value was 0.04.

Results

Mean limb alignment (hip-to-ankle axis) of the 8 intact knees (i.e. before performing the osteotomy) was 1° valgus (range 4° valgus to 1° varus). In full extension, intact knees had mean valgus opening of $1.9 \pm 0.1^\circ$ (Fig. 4). When the sMCL was sectioned, valgus opening increased to $3.8 \pm 0.3^\circ$ ($p < 0.01$). When the dMCL section was added, valgus opening increased to $5.6 \pm 0.6^\circ$ ($p = 0.04$ for comparing “Cut sMCL + cut dMCL” scenario to “Cut sMCL scenario”), and when the ACL was sectioned as well, valgus opening increased further to $6.8 \pm 0.5^\circ$ but this was not significant ($p = \text{n.s.}$ for comparing “Cut sMCL + cut dMCL + cut ACL” scenario to “Cut sMCL + cut dMCL” scenario). In full extension, reductions observed in valgus opening after lateral opening wedge DFO compared to before the DFO were not significant in either “Cut sMCL scenario”, “Cut sMCL + cut dMCL” scenario, or “Cut sMCL + cut dMCL + cut ACL” scenario (i.e. from 3.8 ± 0.8 to $3.4 \pm 0.8^\circ$,

Fig. 4 Valgus opening in 0° and in 30° knee flexion in each scenario. Comment: $p < 0.01$ for all comparisons of valgus opening in 0° and in 30° flexion between each of the scenarios versus the “Intact” knee scenario



$p = n.s.$, from 5.6 ± 0.6 to $5.2 \pm 0.5^\circ$, $p = n.s.$, and from $6.8 \pm 0.5^\circ$ to $6.1 \pm 0.5^\circ$, $p = n.s.$, respectively).

With 30° of knee flexion, the intact knee had valgus opening of $2.9 \pm 0.1^\circ$. When the sMCL was sectioned, valgus opening increased to $6.5 \pm 0.5^\circ$ ($p < 0.01$). When the dMCL section was added, valgus opening increased to $9.9 \pm 0.8^\circ$ ($p < 0.01$ for comparing “Cut sMCL + cut dMCL” scenario to “Cut sMCL” scenario), and when the ACL was sectioned as well, valgus opening increased further to $12.5 \pm 1^\circ$ ($p = 0.02$ for comparing “Cut sMCL + cut dMCL + cut ACL” scenario to “Cut sMCL + cut dMCL” scenario). Comparing valgus opening after lateral opening wedge DFO versus before the osteotomy in 30° knee flexion revealed that in the “Cut sMCL” scenario, valgus opening decreased after the osteotomy by a mean of 14 % (i.e. from $6.5 \pm 0.5^\circ$ to $5.6 \pm 0.5^\circ$, $p = 0.01$). In four of eight specimens, valgus opening after DFO with knee flexed to 30° decreased by 21–36 %, corresponding to reductions of between 1° and 2° in the “Cut sMCL” scenario.

Discussion

The most important finding was that in 30° of knee flexion, medial opening in the scenario of “cut sMCL” decreased by up to 36 % after a lateral opening DFO was performed, with a mean reduction of 14 %. This confirmed our study hypothesis that in a medial ligament sectioned knee, lateral opening wedge DFO may result in decreased medial laxity. This effect, however, was not demonstrated in full extension in the “cut sMCL” scenario or in the “cut sMCL + cut dMCL + cut ACL” scenario, possibly due to the contribution of the posteromedial capsule to restrain valgus loads in extension, which was not sectioned in our model. [4]. Though no previous data exist to our knowledge that quantified the effect of varus-producing osteotomies on medial knee opening in the setting of medial ligaments sectioning, a recent cadaveric model demonstrated that a valgus-directed medial opening wedge proximal tibial osteotomy (PTO) resulted in reduction in lateral knee opening in posterolateral ligament-deficient

knees [7]. In that study, in 30° flexion, after transection of the postero-lateral corner structures (i.e. fibular collateral ligament, popliteus tendon, popliteo-fibular ligament), lateral knee opening increased by 5.9° to applied varus moment compared to the intact knee ($p < 0.001$), but it increased only by 1.6° when a medial opening wedge PTO was added compared to the intact knee ($p < 0.04$). The reduction in lateral knee opening after performing the PTO was significant ($p < 0.001$). The investigators found that the majority of tightening in their biomechanical test set-up was recorded at the superficial MCL. They theorized that the reduction in static varus laxity observed following the PTO may have been partially related to a secondary tightening effect of the osteotomy on structures that cross the knee joint and the osteotomy site and attach to the MCL, but actually act as restraints to varus laxity (i.e. expansions of the posterior capsule and semimembranosus, as well as capsule fibres over the popliteus muscle). In the model presented in this study, a decrease in medial opening after a lateral opening wedge DFO was observed in 30° flexion and therefore may have reflected to some extent mirroring of the effect shown on lateral knee opening with transected postero-lateral structures after performing a medial opening wedge PTO [7]. However, we cannot attribute our findings to a theoretical effect of the osteotomy on either of the collateral ligaments, since the osteotomy was proximal to their femoral insertions. Instead, other soft tissue elements that cross the knee joint from more proximal origins on the femur or pelvis to distal insertions on the tibia such as the hamstrings tendons, the semimembranosus and possibly the iliotibial band could have played a role in this reduction, since changing the knee axis changes their vector of action and possibly the tension through these tissues. However, we did not measure the tension applied by these tissues during the valgus load in our model, and the effect of these tendons would likely be more important in vivo compared to a cadaver specimen.

This model also confirmed that both the MCL and the ACL provided restraint to valgus opening in 0° as well as in 30° of knee flexion, and sectioning of these components resulted in significant increases in valgus opening. This role becomes more important for knee stability when valgus alignment is present since the forces on these tissues during weight-bearing increase due to the increased valgus moment. Following a lateral opening wedge DFO, the valgus moment on the medial restraints is reduced. Addressing the ligament laxity with reconstruction of either the MCL or the ACL, or both, without correcting the valgus alignment may result in failure of these ligament reconstructions while correcting the alignment first with an osteotomy may avoid the need to perform ligament reconstruction.

An inherent limitation of the model is that all specimens had normal alignment. This may limit the applicability of the model to a valgus-aligned knee (due to a hypoplastic lateral femoral condyle), which was the clinical situation for which we performed the osteotomy in the case described. Another limitation is that we did not section the posterior oblique ligament which also plays a role in resisting valgus laxity [17], and therefore may have not recorded the complete effect of a lateral opening wedge DFO on medial knee laxity in the medial-structure-transected knee.

In summary, for patients that present with an unstable, valgus-malaligned knee with ACL and MCL laxity, corrective DFO should be considered because it can improve medial knee stability by decreasing valgus moments during the stance phase of gait and possibly also by improving static valgus restraint.

Conclusion

In superficial MCL-transected knees, medial laxity at 30° of knee flexion decreased after lateral opening wedge DFO. However, the clinical relevance of the laxity decrease observed remains uncertain since the reduction was small in magnitude.

References

1. Badhe NP, Forster IW (2002) High tibial osteotomy in knee instability: the rationale of treatment and early results. *Knee Surg Sports Traumatol Arthrosc* 10:38–43
2. Feeley BT, Muller MS, Allen AA, Granchi CC, Pearle AD (2009) Biomechanical comparison of medial collateral ligament reconstructions using computer-assisted navigation. *Am J Sports Med* 37:1123–1130
3. Goradia VK, Van Allen J (2002) Chronic lateral knee instability treated with a high tibial osteotomy. *Arthroscopy* 18:807–811
4. Grood ES, Noyes FR, Butler DL, Suntay WJ (1981) Ligamentous and capsular restraints preventing straight medial and lateral laxity in intact human cadaver knees. *J Bone Joint Surg Am* 63:1257–1269
5. Hufner T, Geerling J, Kfuri M Jr, Gansslen A, Citak M, Kirchoff T, Sott AH, Krettek C (2003) Computer assisted pelvic surgery: registration based on a modified external fixator. *Comput Aided Surg* 8:192–197
6. Khadem R, Yeh CC, Sadeghi-Tehrani M, Bax MR, Johnson JA, Welch JN, Wilkinson EP, Shahidi R (2000) Comparative tracking error analysis of five different optical tracking systems. *Comput Aided Surg* 5:98–107
7. LaPrade RF, Engebreetsen L, Johansen S, Wentorf FA, Kurtenbach C (2008) The effect of a proximal tibial medial opening wedge osteotomy on posterolateral knee instability. *Am J Sports Med* 36:956–960
8. Markolf KL, Mensch JS, Amstutz HC (1976) Stiffness and laxity of the knee: the contributions of the supporting structures. A quantitative in vitro study. *J Bone Joint Surg Am* 58:583–594

9. McDermott AG, Finklestein JA, Farine I, Boynton EL, MacIntosh DL, Gross A (1988) Distal femoral varus osteotomy for valgus deformity of the knee. *J Bone Joint Surg Am* 70:110–116
10. Paley D, Bhatnagar J, Herzenberg JE, Bhave A (1994) New procedures for tightening knee collateral ligaments in conjunction with knee realignment osteotomy. *Orthop Clin North Am* 25:533–555
11. Pearle AD, Solomon DJ, Wanich T, Moreau-Gaudry A, Grenchi CC, Wickiewicz TL, Warren RF (2007) Reliability of navigated knee stability examination: a cadaveric evaluation. *Am J Sports Med* 35:1315–1320
12. Phisitkul P, Wolf BR, Amendola A (2006) Role of high tibial and distal femoral osteotomies in the treatment of lateral-posterolateral and medial instabilities of the knee. *Sports Med Arthrosc Rev* 14:96–104
13. Seering WP, Piziali RL, Nagel DA, Schurman DJ (1980) The function of the primary ligaments of the knee in varus-valgus and axial rotation. *J Biomech* 13:785–794
14. Terry GC, Cimino PM (1992) Distal femoral osteotomy for valgus deformity of the knee. *Orthopedics* 15:1283–1289
15. Van Damme G, Defoort K, Duclombier Y, Van Glabbeek F, Bellemans J, Victor J (2005) What should the surgeon aim for when performing computer assisted total knee arthroplasty? *J Bone Joint Surg Am* 87:52–58
16. Veltri DM, Warren RF (1994) Operative treatment of posterolateral instability of the knee. *Clin Sports Med* 13:615–627
17. Wijdicks CA, Griffith CJ, Johansen S, Engebretsen L, LaPrade RF (2010) Injuries to the medial collateral ligament and associated medial structures of the knee. *J Bone Joint Surg Am* 92-A:1266–1280