Hockey injuries: a pediatric sport update

Michael K. Shindle[a], Robert G. Marx[a], Bryan T. Kelly[a], Les Bisson[b] and Charles J. Burke III[c]

[a]Department of Orthopedic Surgery, Hospital for Special Surgery, New York, [b]State University of New York at Buffalo, Buffalo, New York and [c]University of Pittsburgh Medical Center, Pittsburgh, Pennsylvania, USA

Correspondence to Michael K. Shindle, MD, Hospital for Special Surgery, 535 East 70th Street, New York, NY 10021, USA
Tel: +1 917 941 6796; fax: +1 212 606 1477; e-mail: shindlem@hss.edu

Current Opinion in Pediatrics 2010, 22:54–60

Purpose of review

Ice hockey is a fast-paced sport played by an increasing number of children and teens across the nation.

Recent findings

The risk of injury in youth hockey is high due to contact from body checking. Youth hockey programs need to educate players, coaches, and parents about the importance of knowing and following the rules as well as the dangers of body checking another player from behind.

Summary

In this article, we will present an overview of the types and rates of injuries that occur in ice hockey and then present a detailed review of hip/groin injuries that are commonly diagnosed in these athletes.

Keywords

femoroacetabular impingement, high ankle sprain, ice hockey, sports hernia

Curr Opin Pediatr 22:54–60
© 2010 Wolters Kluwer Health | Lippincott Williams & Wilkins
1040-8703

Introduction

Ice hockey is a collision team sport played by approximately 350 000 children and adolescents under the auspices of USA Hockey, Inc., the national governing body for amateur ice hockey [1,2]. More than 80 percent of over 35 000 registered teams play in the age classifications 18 and under, prompting the Youth Council of USA Hockey to emphasize the educational and recreational values of ice hockey [3••].

The risk for injury in youth hockey is high due to contact from body checking. Hockey-related fatality and injury rates are more than twice as high as those in football [4]. Overall, body checking/collisions are the greatest cause of injury, accounting for 31.7% of injuries, followed by stick-induced injuries (18.2%), puck (14.0%), boards (10.5%), and 'no-contact' injuries (8.8%) [5]. On average, contusions are the most commonly diagnosed injury (24.3%), followed by sprains (17.3%), lacerations (16.2%), strains (12.1%), and fractures (8.1%) [5]. In general, 'above shoulder' injuries are the most common in ice hockey (26.1%) and include concussions, lacerations, and dental injuries. These are followed by knee (13.1%), shoulder (12.6%), hip/thigh/groin (11.9%), and hand/finger injuries (6.9%; Table 1) [5]. An epidemiological study of high school hockey injuries revealed 75 injuries per 100 players during a single season. Contusions were the most common, but injuries to the head and neck accounted for 22% of all injuries [6]. In a study of college men's ice hockey in the United States, concussion (18.6%) was the most common injury, followed by knee medial collateral ligament sprains, acromioclavicular joint injuries, and ankle sprains [7].

In the 1960s, an alarming number of facial injuries in youth hockey players led to the mandatory use of helmets with a face mask [8]. The helmet–face mask combination was remarkably successful in virtually eliminating facial trauma, but led to an increase in the number of neck and spinal injuries, possibly due to the false sense of protection from serious injury [9]. Body checking contributes not only to the number of injuries sustained but also to their severity. In a study of 117 hockey players with spine or spinal cord injuries, the most common cause of such injury was a push or check from behind (by an opponent) that catapulted the player headfirst into the boards [8]. Nevertheless, collision is allowed in boys' ice hockey at the Peewee level (11–12-year-olds), even though size and physical maturity differ considerably among boys less than 16 years of age. It has been shown that weight can range from 34 to 70 kg for Peewees (11–12-year-olds) and from 37 to 90 kg for Bantams (13–14-year-olds), which has a great potential for serious injury [10].

Since studies have shown that a high proportion of youth hockey injuries are attributable to checking and that limiting checking can reduce injuries, the American Academy of Pediatrics recommends body checking should not be allowed in youth hockey for children of

Copyright © Lippincott Williams & Wilkins. Unauthorized reproduction of this article is prohibited.

Table 1 Summary of common injuries sustained during ice hockey based on anatomic location

Injury location	Diagnosis
Head and face	Concussions
	Lacerations
	Dental fractures
Neck	Cervical spine fractures
Shoulder	Acromioclavicular sprain
	Clavicle fracture
	Shoulder dislocation
Elbow	Bursitis
Wrist and hand	Scaphoid fractures
	Ulnar collateral ligament sprain
Back	Lumbar paraspinal muscle strain
	Spondylolysis
Hip	Femoroacetabular impingement
	Adductor muscle strain
	Hip flexor strain
Thigh	Quadriceps contusion
Knee	Medial collateral ligament sprain
Ankle	High ankle sprain

15 years of age or less; good sportsmanship programs, such as the fair-play concept, have been shown to reduce injury and penalty rates and should be adopted for all levels of youth hockey; and youth hockey programs need to educate players, coaches, and parents about the importance of knowing and following the rules as well as the dangers of body checking another player from behind [11]. Despite these recommendations, hockey will remain a contact sport, and the ideal age to learn the skills associated with delivering and receiving body checks is unclear.

Upper extremity/shoulder

Injuries to the upper extremity in ice hockey are relatively common and serious. Body checking, contact with other players, striking against the boards, and blows by sticks are the usual mechanisms of injury. A direct blow to the shoulder can result in a clavicle fracture (Fig. 1a–b), acromioclavicular joint separation, or shoulder dislocation [12]. Elbow trauma may lead to fractures of the radial head, olecranon, distal humerus, or elbow dislocation. Injuries of the pediatric elbow can occur from a fall on an outstretched hand.

Gamekeeper's thumb, rupture of the ulnar collateral ligament of the thumb, may occur when a player falls with the stick in hand. Molsa *et al.* [12] noted a high risk of fractures in players between 15 and 19 years of age, which may be explained by the increased velocity in skating, relative immaturity of bones, and increased body mass and strength.

The shoulder, elbow, and wrist have traditionally been considered well protected areas of an ice hockey player. However, shoulder pads in ice hockey are quite flexible and do not give the same protection as is provided by those used in American football. Hockey gloves have to be flexible in order to permit stick handling, so they are not able to prevent fractures such as distal radius fractures or scaphoid fractures, which are seen in hockey players.

Figure 1 Serendipity views of a 14-year-old boy after sustaining a collision with another player

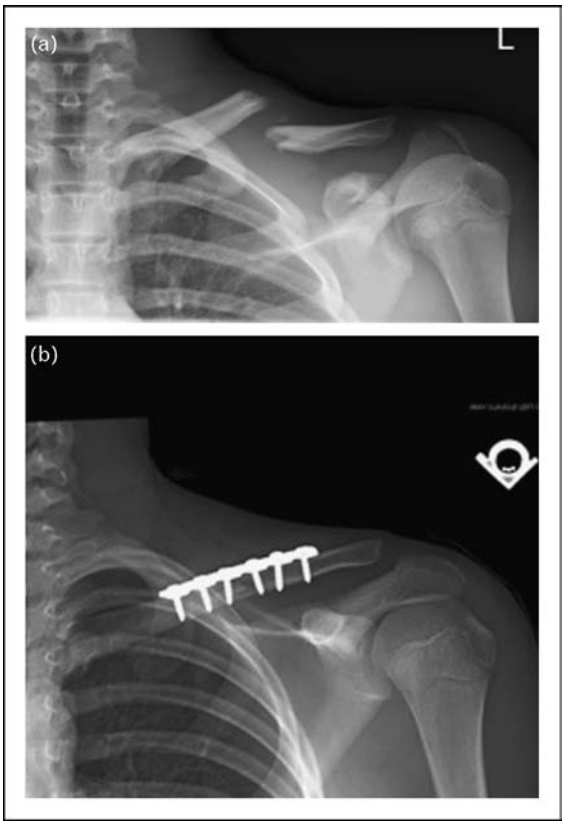

Serendipity views of a 14-year-old boy after sustaining a collision with another player demonstrating (a) a middle third displaced clavicle fracture. He underwent open reduction internal fixation (b) without complication.

Foot/ankle

Sprains of the ligamentous structures about the ankle have been established as one of the most common injuries in sports and a source of significant lost playing time for the athlete. In general, lateral ankle sprains are the most common type of injury [13]. The lateral ligamentous complex of the ankle consists of three ligaments: the anterior talofibular ligament (ATFL), the calcaneofibular ligament (CFL), and the posterior talofibular ligament (PTFL). Clinical examination should include the anterior drawer test and talar tilt test to determine whether the ankle sprain is stable or unstable. The anterior drawer test is performed by securing the distal leg with one hand and applying an anterior pull on the heel with the foot held in gentle plantar flexion. Excessive anterior translation (>8 mm) or lack of a firm endpoint indicates a positive test [13]. If these tests are

Copyright © Lippincott Williams & Wilkins. Unauthorized reproduction of this article is prohibited.

negative, the ankle is considered to be stable and treatment can proceed in a symptomatic manner. If the ankle is classified as unstable, more aggressive treatment with some form of immobilization is warranted.

Another type of sprain that can occur involves the syndesmotic ligaments and the lay terminology for this injury is a 'high ankle sprain.' When the sprain results in a complete rupture of the ligaments, a diastasis can occur with separation of the distal ends of the tibia and fibula [14]. Syndesmosis sprains are a continuum of injury ranging from a minor sprain to frank diastasis [13]. High ankle sprains have been estimated to occur in as many as 1–18% of all ankle sprains [15–17]. High ankle sprains have received increased attention in the literature because many of these injuries go undiagnosed and are the source of chronic ankle pain and arthrosis in many patients. Calcification of the distal tibiofibular syndesmosis was reported in 32% of professional football players attending training camp, which suggests a much higher incidence of injury [18]. The squeeze test can be used to diagnose sprains of the tibiofibular syndesmosis and is performed by compressing the fibula and tibia proximal to the midpoint of the calf, which causes separation at the origin and insertion of the anterior inferior tibiofibular ligament. Although syndesmosis sprains are less common in sports than lateral ankle sprains (ATFL), several studies have demonstrated that syndesmosis sprains represent a significant injury in hockey players and, unlike in other sports, are a more common injury than lateral ankle sprains [7,19]. Thus, a high index of suspicion of high ankle sprains in hockey players is necessary. Creation of the syndesmotic injury by external rotation is unique to skiing and hockey because the ankle is constrained by a rigid ski boot or hockey skate. In addition, the elevation provided by the hockey skate blade, combined with high speeds and rapid direction changes, places the ankle at higher potential for torque injury, often related to 'catching a rut' in the ice with the skate blade.

Pelvis/hip

Groin pain is a common entity in ice hockey players. However, the cause of this pain may be difficult to elucidate because of the complex local anatomy and the multitude of differential diagnoses. In addition, the conditions responsible for groin pain are often insidious and diffuse with nonspecific presentations. To complicate matters even more, these athletes may also have more than one diagnosis that accounts for their symptoms, such as a player with a sports hernia and acetabular labral tear.

The most common musculoskeletal causes of chronic groin pain are adductor muscle strains and osteitis pubis [20]. Other causes of hip pain are included in Table 2 [21•,22]. The pathologic entity known as sports hernia or athletic pubalgia is an occult hernia caused by a tear or weakness of the posterior inguinal wall, without a clinically recognizable hernia, which leads to a condition of chronic groin pain [23]. The exact incidence of sports hernia is not known, but several studies have demonstrated that it is quite common in athletes with recalcitrant groin pain despite nonsurgical treatment. Kluin *et al.* [24] found sports hernia to be the cause of chronic groin pain in 39% of their athletes based on diagnostic endoscopy. The most common physical findings include local tenderness over the pubic tubercle, conjoined tendon, and midinguinal region; a tender, dilated superficial inguinal ring; tenderness of the posterior wall of the inguinal canal; and pain with a resisted sit-up.

Table 2 Differential diagnosis of hip pain

Traumatic	Subluxation/dislocation
	Stress fracture/fracture
	Hematoma
	Contusion
Labral disorder	Femoroacetabular impingement
	Laxity
	Trauma
	Dysplasia
Infectious/tumor/ metabolic	Septic arthritis
	Osteomyelitis
	Benign bone and soft tissue neoplasms
	Malignant bone and soft tissue neoplasms
	Metastatic bone disease
Inflammatory	Rheumatoid arthritis
	Reiter's syndrome
	Psoriatic arthritis
Chondral disorder	Lateral impaction
	Avascular necrosis
	Loose bodies
	Chondral shear injury
	Osteoarthritis
Capsule disorder	Laxity
	Adhesive capsulitis
	Synovitis/inflammation
Nonmusculoskeletal causes	Psoas muscle abscess
	Spine
	Hernia
	Endometriosis
	Ovarian cyst
	Peripheral vascular disease
Unknown cause	Transient osteoporosis of the hip
	Bone marrow edema syndrome
Synovial proliferative disorders	Pigmented villonodular synovitis
	Synovial chondromatosis
	Chondrocalcinosis
Metabolic	Paget's disease
	Primary hyperparathyroidism
Extraarticular disorder	Coxa saltans (internal/external)
	Psoas impingement
	Abductor tears (rotator cuff tears of the hip)
	Athletic pubalgia
	Trochanteric bursitis
	Ischial bursitis
	Osteitis pubis
	Piriformis syndrome
	Sacroiliac disorder
	Tendonitis (hip flexors, abductors, adductors)

Obtained with permission from [22].

Copyright © Lippincott Williams & Wilkins. Unauthorized reproduction of this article is prohibited.

The physical examination is also extremely useful in determining the cause of chronic groin pain. A patient with a stress fracture usually has pain with axial loading of the leg. Pain and clicking with passive hip range of motion is suggestive of an acetabular labral tear. Pain with flexion, adduction, and internal rotations is suggestive of femoroacetabular impingement. Pain with resisted adduction and passive abduction of the thigh is suggestive of an adductor muscle strain. Pain with resisted hip flexion with tenderness to palpation over the rectus femoris suggests a rectus femoris strain. The patient with osteitis pubis usually has tenderness to palpation of the pubic symphysis.

Imaging

On the basis of the history and physical examination, various categories can be eliminated and the differential diagnosis further narrowed. The conventional radiograph then can provide a great deal of information and should include an anteroposterior radiograph of the pelvis, a Dunn lateral radiograph (90° flexion, 20° abduction), and a false-profile radiograph [25]. The anteroposterior radiograph of the pelvis should be carefully examined in order to exclude malalignment, impingement, subtle fractures, or evidence of dysplasia. A Dunn lateral radiograph is useful for identifying a cam lesion associated with femoroacetabular impingement (Fig. 2), and a false-profile radiograph (Fig. 3) is useful in evaluating coverage of the anterior portion of the femoral head.

Despite a thorough history and physical examination, it is oftentimes difficult to distinguish extraarticular from intraarticular pain. In nearly all patients with hip pain, a fluoroscopically or ultrasound-guided intraarticular injection of anesthetic medication is invaluable as a tool to determine whether the hip pain is due to disorder [26].

Figure 2 Dunn lateral radiograph (elongated-neck lateral view) of the hip, demonstrating an osseous offset (yellow arrow) at the femoral head–neck junction, indicating a cam lesion

Obtained with permission from [21•].

Figure 3 A false-profile view of the hip

This is a true lateral radiograph of the acetabulum, which allows measurement of coverage of the anterior portion of the femoral head (anterior center edge angle). A value of more than 25° is normal, whereas a value of 20° or less is consistent with acetabular dysplasia. (Obtained with permission from [21•]).

In most cases, an MRI is indicated to evaluate the acetabular labrum and articular cartilage, and to screen the pelvis for other causes of pain such as infection or tumor [27]. Evaluation of patients with osseous abnormalities can often be facilitated with a computed tomography scan with three-dimensional reconstructed images.

Labral tears

Injuries to the acetabular labrum are the most common pathologic findings identified during hip arthroscopy [28]. The labrum is a fibrocartilaginous structure that provides some structural resistance to vertical and lateral motion of the femoral head within the acetabulum and has an important sealing function that limits fluid expression from the joint space to protect the cartilage layers of the hip [29,30]. Mechanical symptoms and restricted range of motion are usually present with labral tears. Patients with clinical signs, magnetic resonance findings consistent with a labral tear (Fig. 4a–b), and persistent hip pain despite nonsurgical management are candidates for hip arthroscopy.

Femoroacetabular impingement

Two distinct types of femoroacetabular impingement (FAI) have been described, cam and pincer [31]. Cam

Copyright © Lippincott Williams & Wilkins. Unauthorized reproduction of this article is prohibited.

Figure 4 Sagittal fast spin echo MRI of the hip

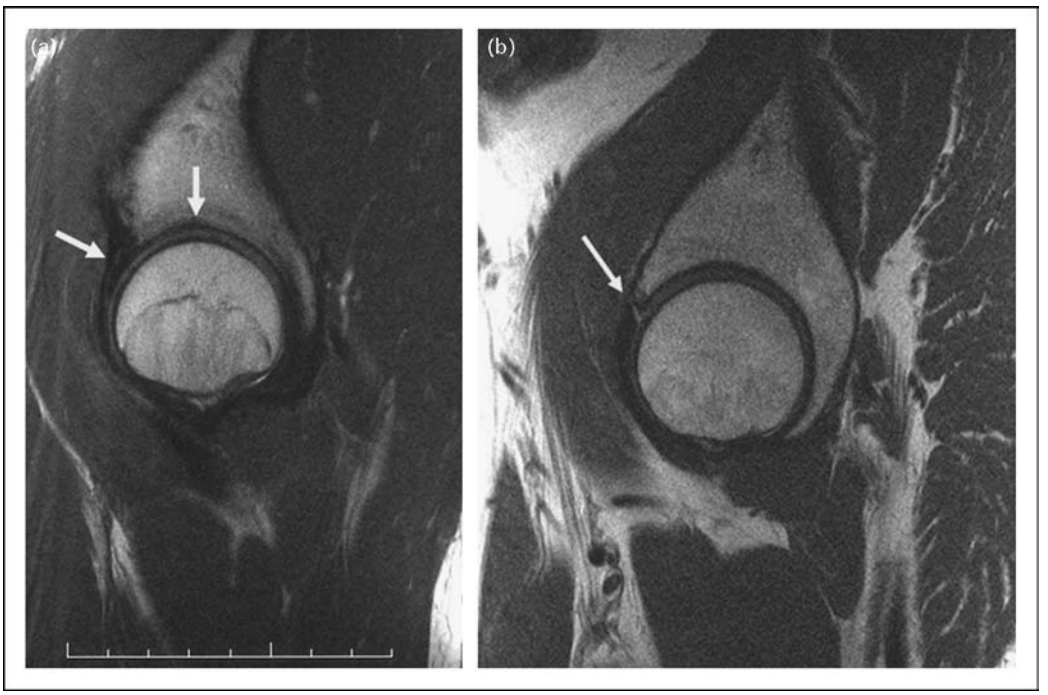

Sagittal fast spin echo (FSE) MRI of the hip showing (a) a normal anterior labrum (arrows) as a triangular focus of low signal and normal articular cartilage of the acetabulum. Sagittal FSE MRI scan of the hip showing (b) a nondisplaced anterior labral tear (arrow).

impingement is the result of an abnormally shaped femoral head, which contacts a normal spherical acetabulum, most commonly in hip flexion and internal rotation. When the aspherical head–neck junction of the femur enters the acetabulum, it displaces the labrum toward the capsule and applies disproportionate load to the adjacent articular cartilage of the acetabulum. This leads to chondral delamination and detachment of the labrum from the acetabular rim.

Pincer impingement involves an abnormal acetabulum with retroversion or overcoverage of the femoral head [30]. This retroversion or overcoverage causes impingement of the labrum between the acetabulum and the femoral neck, resulting in crushing, degeneration, and eventual ossification of the labrum (Fig. 5). Chondral injuries are generally less severe than in cam impingement.

It has been demonstrated that FAI is a major cause of hip pain, reduced range of motion, and decreased performance in the athletic population [22,32]. Such injuries are common in a broad range of sports, including hockey, ballet, football, and soccer. Athletes usually present with anterior groin pain exacerbated by hip flexion, and physical examination reveals the impingement sign (pain with flexion, adduction, and internal rotation).

Hockey player's syndrome

Hockey player's syndrome is a distant entity that is unique to elite hockey players and involves a tear of

Figure 5 Coronal fast spin echo magnetic resonance image of a patient with combined femoroacetabular impingement with a cam lesion (arrow) and ossification of a torn superior portion of the labrum (arrowhead) consistent with pincer-type impingement

Obtained with permission from [27].

Copyright © Lippincott Williams & Wilkins. Unauthorized reproduction of this article is prohibited.

the external oblique aponeurosis associated with inguinal nerve entrapment [33,34]. The pain is typically worse in the morning, during the slap-shot motion and during the first few strides of skating. The pain may radiate to the hip, scrotum, or back. Pain usually occurs on palpation of the superficial inguinal ring and a palpable gap may occasionally be felt in the external oblique aponeurosis as the supine patient elevates his or her head or actively flexes the hip against resistance. Imaging studies are usually negative. Surgical exploration is the only method currently available to confirm the diagnosis. Irshad *et al.* [33] reported the results of 22 professional hockey players diagnosed with this condition after the failure of conservative treatment. The athletes underwent open surgical repair consisting of ablation of the ilioinguinal nerve and repair of the external oblique aponeurosis with mesh reinforcement. Eighty-six percent of patients were able to continue at the professional level and 82% were pain-free at final follow-up.

Sports hernia

When no hernia is detected on physical examination but the history and physical findings are consistent with a sports hernia, then nonsurgical treatment with rest, anti-inflammatory agents, and stretching and strengthening exercises should be initiated. When symptoms persist for more than 3 months with nonsurgical treatment, then a referral to a general surgeon for open or laparoscopic herniorrhaphy should be considered [23]. In addition, treatment of a contracted or overdeveloped adductor muscle should not be neglected and adductor tenotomy combined with herniorrhaphy should be considered. Meyers *et al.* [35] performed open pelvic floor repair on 157 athletes with chronic groin pain with broad surgical reattachment of the inferolateral edge of the rectus abdominis with its fascial investment to the pubis and adjacent anterior ligaments. Twenty-three percent of patients also underwent combined adductor release and 97% of patients returned to their preinjury activity levels.

Conclusion

Ice hockey is a contact sport that involves body checking at the Peewee level. USA Hockey has placed a special emphasis on coaches properly teaching the skills necessary to legally body check an opponent without intimidation. In addition, the 'Heads Up Hockey' program has emphasized clean play and preventive medicine [36]. In ice hockey, there is a vast array of hip and pelvic problems that may affect an athlete and decrease performance. Sports hernia is increasingly being recognized as a common cause of chronic groin pain in athletes. Additional research is needed to clarify the role of differing training regimens and conditioning exercises that may help prevent these injuries.

References and recommended reading

Papers of particular interest, published within the annual period of review, have been highlighted as:
- • of special interest
- •• of outstanding interest

Additional references related to this topic can also be found in the Current World Literature section in this issue (p. 120).

1 Brust JD, Roberts WO, Leonard BJ. Gladiators on ice: an overview of ice hockey injuries in youth. Med J Allina 1996; 5:26–29.

2 USA Hockey, Inc. Annual Report 2007/2008. Colorado Springs, CO: USA Hockey, Inc.; 2008.

3 •• USA Hockey. '2009-11 Official Rules of Ice Hockey.' Colorado Springs, CO: USA Hockey, Inc.; 2009.
USA Hockey is the national governing body for the sport of ice hockey in the United States. The goal of USA Hockey is to promote a safe and positive playing environment for all participants while continuing to focus on skill development and enjoyment of the sport. This document has 'Points of Emphasis' including fair play and philosophy of youth hockey and should be reviewed by anyone involved with the game of ice hockey.

4 Marchie A, Cusimano M. Body checking and concussions in ice hockey: should our youth pay the price? CMAJ 2003; 169:124–128.

5 Azuelos YH, Pearsall DJ, Turcotte R, Montgomery DL. A review of ice hockey injuries: location, diagnosis, mechanism. Safety in ice hockey. 4th volume. In: Pearsall DJ, Ashare AB, editors. West Conshohocken, PA: ASTM International; 2004. pp. 59–69.

6 Gerberich SG, Finke R, Madden M, *et al.* An epidemiological study of high school hockey injuries. Childs Nerv Syst 1987; 3:59–64.

7 Flik K, Lyman S, Marx RG. American collegiate men's ice hockey. An analysis of injuries. Am J Sports Med 2005; 33:183–187.

8 Reynen PD, Clancy WG. Cervical spine injury, hockey helmets and face masks. Am J Sports Med 1994; 22:167–170.

9 Tator CH, Edmonds V, Lapczak L. Spinal injuries in ice hockey players 1986–87. Can Med Assoc J 1991; 34:63–69.

10 Brust JD, Leonard BJ, Pheley A, *et al.* Children's ice hockey injuries. Am J Dis Child 1992; 146:741–747.

11 American Academy of Pediatrics. Committee on Sports Medicine and Fitness. Safety in youth ice hockey: the effects of body checking. Pediatrics 2000; 3:657–658.

12 Molsa J, Kujala U, Myllynen P, *et al.* Injuries to the upper extremity in ice hockey: analysis of a series of 760 injuries. Am J Sports Med 2003; 31:751–757.

13 Clanton TO, McGarvey W. Athletic injuries to the soft tissues of the foot and ankle. Surgery of the foot and ankle. In: Coughlin MJ, Mann RA, Saltzman CL, editors. Philadelphia, PA: Mosby Elsevier; 2007. pp. 1425–1563.

14 Bose K. Congenital diastasis of the inferior tibiofibular joint: report of a case. J Bone Joint Surg Am 1976; 58:886–887.

15 Boytim MJ, Fischer DA, Neumann L. Syndesmotic ankle sprains. Am J Sports Med 1991; 19:294–298.

16 Gerber JP, Williams GN, Scoville CR, *et al.* Persistent disability associated with ankle sprains: a prospective examination of an athletic population. Foot Ankle Int 1998; 19:653–660.

17 Hopkinson WJ, St. Pierre P, Ryan JB, *et al.* Syndesmosis sprains of the ankle. Foot Ankle 1990; 10:325–330.

18 Vincelette P, Laurin CA, Levesque HP. The footballer's ankle and foot. Can Med Assoc J 1972; 107:872–875.

19 Wright RW, Barile RJ, Surprenant DA, Matava MJ. Ankle syndesmosis sprains in national hockey league players. Am J Sports Med 2004; 32: 1941–1945.

20 Lovell G. The diagnosis of chronic groin pain in athletes: a review of 189 cases. Aust J Sci Med Sport 1995; 27:76–79.

21 • Shindle MK, Voos JE, Nho SJ, *et al.* Arthroscopic management of labral tears in the hip. J Bone Joint Surg Am 2008; 90 (Suppl 4):2–19.
This paper reviews the main causes of labral tears in the hip, including labral tears secondary to trauma, FAI, instability, psoas impingement, dysplasia, and degenerative arthritis. The article also discusses relevant anatomy and history, typical findings on physical examination, types of imaging studies performed, and treatment options, with a focus on the arthroscopic management of labral injuries, including labral repair.

22 Shindle MK, Voos JE, Heyworth BE, *et al.* Hip arthroscopy in the athletic patient: current techniques and spectrum of disease. J Bone Joint Surg Am 2007; 89 (Suppl 3):29–43.

Copyright © Lippincott Williams & Wilkins. Unauthorized reproduction of this article is prohibited.

23 Farber AJ, Wilckens JH. Sports hernia: diagnosis and therapeutic approach. J Am Acad Orthop Surg 2007; 15:507–514.

24 Kluin J, den Hoed PT, van Linschoten R, *et al.* Endoscopic evaluation and treatment of groin pain in the athlete. Am J Sports Med 2004; 32:944–949.

25 Manaster BJ, Zakel S. Imaging of femoral acetabular impingement syndrome. Clin Sports Med 2006; 25:635–657.

26 Byrd JW, Jones KS. Diagnostic accuracy of clinical assessment, magnetic resonance imaging, magnetic resonance arthrography, and intra-articular injection in hip arthroscopy patients. Am J Sports Med 2004; 32:1668–1674.

27 Shindle MK, Foo LF, Kelly BT, *et al.* Magnetic resonance imaging of cartilage in the athlete: current techniques and spectrum of disease. J Bone Joint Surg Am 2006; 88 (Suppl 4):27–46.

28 Kelly BT, Weiland DE, Schenker ML, *et al.* Arthroscopic labral repair in the hip: surgical technique and review of the literature. Arthroscopy 2005; 21:1496–1504.

29 Seldes RM, Tan V, Hunt J, *et al.* Anatomy, histologic features and vascularity of the adult acetabular labrum. Clin Orthop Relat Res 2001; 382:232–240.

30 Ferguson SJ, Bryant JT, Ganz R, Ito K. The influence of the acetabular labrum on hip joint cartilage consolidation: a poroelastic finite element model. J Biomech 2000; 33:953–960.

31 Ganz R, Parvizi J, Beck M, *et al.* Femoroacetabular impingement: a cause for osteoarthritis of the hip. Clin Orthop 2003; 417:112–120.

32 Philippon MJ, Schenker ML. Arthroscopy for the treatment of femoroacetabular impingement in the athlete. Clin Sports Med 2006; 25:299–308.

33 Irshad K, Feldman LS, Lavoie C, *et al.* Operative management of 'hockey groin syndrome': 12 years of experience in National Hockey League players. Surgery 2001; 130:759–764.

34 Lacroix VJ, Kinnear DG, Mulder DS, Bown RA. Lower abdominal pain syndrome in national hockey league players: a report of 11 cases. Clin J Sport Med 1998; 8:5–9.

35 Meyers WC, Foley DP, Garrett WE, *et al.* Management of severe lower abdominal or inguinal pain in high-performance athletes: PAIN (performing athletes with abdominal or inguinal neuromuscular pain study group). Am J Sports Med 2000; 28:2–8.

36 USA Hockey. 'Heads Up Hockey Program Guide.' USA Hockey Safety and Protective Equipment Committee: Colorado Springs, CO; 1996.

Copyright © Lippincott Williams & Wilkins. Unauthorized reproduction of this article is prohibited.